Hassan, A., Bamaga, A.K., Cupler, E.J., Al-Hashel, J., Alabdali, M.M., Alanazy, M.H., et al. A Multidisciplinary Perspective Addressing the Diagnostic Challenges of Late-Onset Pompe Disease in the Arabian Peninsula Region Developed from an Expert Group Meeting**.** J. Neuromuscul. Dis. 2022, 9, 661–673.

4.Lilleker, B.J., Keh, Y.S., Roncaroli, F., Sharma, R., Roberts, M. Metabolic myopathies: a practical approach. 2018, 18, 14–26.

5. Tarnopolsky, M.A. Metabolic Myopathies. Contin Lifelong Learn Neurol. 2016, 2, 1829–1851.

6.Toscano, A., Barca, E., Musumeci, O. Update on diagnostics of metabolic myopathies**.** Curr Opin Neurol. 2017, 30,553–562.

7.Urtizberea, A.J., Severa, G., Malfatti, E. Metabolic Myopathies in the Era of Next-Generation Sequencing. 2023, 22, 14,954.

8. Zutt, R., van der Kooi, A., Linthorst, G., Wanders, R., de Visser, M. Rhabdomyolysis: Review of the literature**.** Neuromuscul Disord. 2014, 24, 651–659.

UNUSUAL PRESENTATION OF HYDATID CYST AS PRIMARY AND SOLITARY MANIFESTATION OF THE DISEASE IN CENTRAL NERVOUS SYSTEM: CASE REPORT AND LITERATURE REVIEW

Renish Padshala

NHL Municipal medical College and SVP Hospital
Ahmedabad , India

INTRODUCTION

Human echinococcosis is a zoonotic parasitic disease caused by Echinococcus granulosus, which forms larval cysts in the human tissue. Echinococcus granulosus is a tapeworm that lives in the intestines of dogs that are the definitive hosts. Infected dogs pass tapeworm eggs in their stool, which can be consumed by sheep, cattle, goats, pigs, and accidentally humans as intermediate hosts. The two primary types affecting humans are caused by Echinococcus granulosus and Echinococcus multilocularis. The liver is the most common organ affected, followed by the lungs. Hydatid cysts can also develop in the brain, heart, kidneys, spinal cord, spleen, and other tissues . Hydatid disease in the brain accounts for only 1% - 2% of all cases caused by Echinococcus granulosus infections. Cerebral hydatid cysts are usually located in the supratentorial region and are seldom found in the infratentorial region [1]. Extracranial and spinal hydatid cysts are very rare. Hematogenous spread is the most common route of dissemination of the ova to the central nervous system and the cysts are usually located along the distribution area of the middle cerebral arteries, often in the parietal lobe [2]. The majority (70% - 80%) of intracranial hydatid cysts are found in children [3].Brain hydatid cysts are usually solitary but, on rare occasions, multiple cysts might be encountered. While multiple cysts might be primary, they might also be secondary and related to the rupture of primary cyst [4]. Due to slow growth of the cyst, patients usually present with a large cyst at the time of diagnosis. Typically, cysts initially manifest as focal neurologic deficits or symptoms related to increased intracranial pressure [5]. The optimal management of intracranial hydatid cysts is intact surgical removal of the cyst. Although cerebral hydatid disease accounts for only 1–2 % of cases, it poses a potentially fatal risk, particularly in children and young adults, who represent 50–75 % of all cases . Therefore, the need for timely diagnosis and intervention should be emphasized, especially in low-income countries where healthcare access may be limited.

Case Presentation

A 34 year old male patient from a rural area was admitted to our hospital with a headache for 07 months and left upper limb weakness for 15 days with abnormal movement of left upper and lower limb for 3 days. During admission time, examination revealed a afebrile and conscious patient, hemodynamically stable, the pulse rate, blood pressure, and oxygen levels were normal. Clinical examination findings were unremarkable, and no abnormality in the neurological examination was noted except left hemiparesis with the force of three to fifth in all muscle groups and grade 3 deep tendon reflexes. Blood investigation, C-reactive protein and other tests (serum electrolyte levels, liver function, kidney function, and coagulation tests) were normal.On magnetic resonance imaging before admission (approx 5 months before) , it was initially misdiagnosed as neurological cyst/ arachnoid cyst in the right parietal lobe. After admission in our institute Brain contrast-enhancing magnetic resonance imaging (MRI) showed a large 65x50x51mm cystic intra-axial lesion at the right temporoparietal junction with peripheral diffusion restriction and ring enhancement and surrounding edema and significant mass effect toward left side s/o -cystic glioma/Hydatid cyst/atypical NCC (Figure 1). The patient underwent a right temporoparietal craniotomy under general anesthesia. After dural opening, a limited corticotomy was performed over non-eloquent cortex with preservation of cortical veins. The intra-axial cyst was not in communication with the ventricular system. Cyst delivery was attempted using the Dowling–Orlando technique with gentle hydrodissection using warm normal saline, and cotton patties soaked in hypertonic saline were placed around the operative field. Intraoperative cyst rupture occurred, following which the cavity was immediately irrigated with hypertonic saline. The anesthesiology team monitored for anaphylaxis, and no hemodynamic instability was observed. Complete removal was achieved, followed by watertight dural closure and standard wound closure. The macroscopic analysis of the surgical specimen revealed spherical cysts with whitish walls. Several

pearly white translucent daughter cysts of variable sizes, with clear fluid and membranous structures, were observed inside the cysts. Histopathologic examination of the specimen confirmed the diagnosis of hydatid cyst by visualizing the laminated membrane of the cyst wall. (Figure 2) Our patient was treated with albendazole under supervision of an infectious disease specialist. The patient stayed in the intensive care unit for two days after the operation and was then transferred to the ward. No post-operative complication occurred . He was discharged with long-term prescription of oral albendazole at 400 mg/dose twice daily given in cycles of 28 days interrupted by a 15-day period with a routine monitoring of blood counts and liver function tests (in view of the potential hepatic and hematological adverse effects of albendazole. Treatment of echinococcosis for patients weighing more than 60 kg is albendazole administered PO with meals in a dose of 400 mg twice daily for 28 days. A dose of 15 mg/kg of body weight daily in 2 divided doses (not to exceed total daily dose of 800 mg) has been suggested for patients weighing less than 60 kg. For cystic echinococcosis, the 28-day course may be repeated after 14 days without treatment to a total of 3 treatment cycles.) Oral treatment continued for about three months. After three months of follow-up, left hemiparesis improved, and the left side limbs were raised to four-fifths. At this time brain MRI was normal without residual cyst or any recurrence (Figure 3).

DISCUSSION

Echinococcus granulosus follows a two-host life cycle, with dogs as definitive hosts and humans as accidental intermediate hosts. After ingestion of eggs, larvae penetrate the intestinal wall and disseminate hematogenously, most commonly lodging in the liver (≈75%) and lungs (≈15%), while cerebral involvement remains rare (≈1–2%). [6,7]. Intracranial hydatid cysts may be primary, resulting from direct cerebral infestation, or secondary, typically multiple and associated with systemic disease.[8,9] Cyst growth is slow and influenced by tissue resistance, averaging approximately 1 cm every 5–16 months, which explains the delayed clinical presentation and large lesion size at diagnosis. Consequently, patients most often present with symptoms related to mass effect, predominantly headache and focal neurological deficits in intracranial disease. [10,11,12]. Although cerebral hydatid disease is classically described in children, adult patients with solitary supratentorial cysts are well represented in the literature and therefore do not constitute an exceptional presentation. The age of our patient and the temporoparietal localization are consistent with previously reported adult cases and likely reflect hematogenous dissemination along the middle cerebral artery territory.

CT and MRI are the primary imaging modalities for evaluating intracranial hydatid disease. Classically, CT demonstrates a well-defined, spherical cystic lesion without rim enhancement or perilesional edema, with cyst fluid density similar to or slightly higher than cerebrospinal fluid and rare calcification. On MRI, the lesion typically appears hypointense on T1-weighted images and hyperintense on T2-weighted images, often with a thin hypointense halo corresponding to the cyst wall. The presence of hydatid cysts in other organs, particularly the liver, may further support the diagnosis. [13,14]. The principal value of this case lies in its atypical radiological appearance rather than its demographic or anatomical characteristics. Typical intracranial hydatid cysts are non-enhancing, well-defined cystic lesions without surrounding edema. In contrast, our case demonstrated peripheral ring enhancement, diffusion restriction, and significant perilesional edema—features that substantially complicated the preoperative diagnosis and initially suggested alternative pathologies such as cystic glioma or atypical neurocysticercosis. Such findings have been infrequently reported and are usually attributed to cyst rupture or a localized inflammatory host response.

The principal value of this case lies in its atypical radiological appearance rather than its demographic or anatomical characteristics. Typical intracranial hydatid cysts are classically described as non-enhancing, well-defined cystic lesions isointense to CSF on T1 and hyperintense on T2, notably lacking surrounding perilesional edema or rim enhancement [13, 14]. In stark contrast, our patient presented with peripheral ring enhancement, significant perilesional edema, and restricted diffusion on DWI—features that substantially complicated the preoperative diagnosis and initially mimicked high-grade pathologies such as cystic glioma, brain abscess, or atypical neurocysticercosis.

While such inflammatory imaging features are infrequent, they are not unprecedented and have been documented in specific contexts within the literature. Our findings align closely with cases where the host immune response is heightened due to micro-ruptures or secondary infection. For instance, **Nemati et al. (2010)**reported a giant cerebral hydatid cyst in a child that exhibited significant perilesional edema and rim enhancement, attributing these findings to a localized inflammatory reaction triggered by minor leakage of antigenic fluid through an intact but permeable cyst wall [17]. Similarly, **Abdulla et al. (1988)** described cases of ruptured cerebral hydatid cysts where MRI demonstrated intense ring enhancement and extensive edema, indistinguishable from pyogenic abscesses or high-grade gliomas prior to surgical confirmation [4]. Furthermore, **Menkü et al. (2004)** highlighted a case of a gigantic cyst where diffusion restriction was observed, suggesting that the viscous proteinaceous content of the cyst fluid or the presence of inflammatory debris can mimic the restricted diffusion typically seen in abscesses or cellular tumors [15].

The presence of ring enhancement and edema in our case, despite the absence of overt intraoperative rupture prior to excision, suggests a subclinical leak or a robust hypersensitivity reaction of the host parenchyma to the parasitic antigens. This contrasts with the "cold" appearance of uncomplicated cysts described by **Kammerer (1993)**, where the cyst acts as a passive space-occupying lesion with minimal host reaction [6]. The overlap in imaging features between our case and those of necrotic tumors or abscesses underscores a critical diagnostic pitfall: in endemic regions, the presence of ring enhancement and edema should not automatically exclude hydatid disease. As demonstrated by **Altas et al. (2010)** in their review of giant cysts, reliance on classical "non-enhancing" criteria may lead to misdiagnosis and inappropriate management strategies,

such as biopsy attempts which carry a high risk of anaphylaxis and dissemination [9].

Serological tests have limited reliability in isolated cerebral disease. The Casoni test is positive in only approximately 60% of cases, while ELISA shows variable sensitivity (60–90%) and may yield false-positive results due to cross-reactivity or false-negative results owing to the weak immune response elicited within the central nervous system. [15,16,17]. Consequently, neither imaging nor serology alone is definitive, and final diagnosis requires histopathological confirmation by identification of the parasitic structures. [18].

Surgical removal is the primary method of treatment. Due to the challenges of removing a brain cyst, preoperative diagnosis can be invaluable. These cysts are usually large at the time of operation and have a thin capsule. They also might have adhesions and might be located deep in or close to the ventricular walls requiring careful dissection. Surgical excision without rupture is the preferred treatment approach to prevent recurrence and anaphylactic reactions. The most common surgical approach is that described by Arana-Iniguez and San Julian and consists of forced expulsion of the cyst by hydrodissection introducing hypertonic saline solution under and around the cyst [19]. The Dowling technique is the most effective surgical method for removing cerebral hydatid cysts without causing rupture. For Dowling-Orlando technique, the head is lower than the operation table. Large craniotomy flaps can be made depending on the size and site of the lesion. Surgery area of brain covering cotton soaked with warm normal saline to prevent spillage in case of rupture. Then, the cyst removes and dura closes watertight, bone flap puts back and patient dresses after wound closure. After craniotomy and prior to the incision, the surgical field must be cleaned with scolicidal solution to prevent recurrence because even a minimal spillage can lead to new cysts formation (1 mL of cyst fluid contains 4 000 000 scolices). Intra-operative cyst rupture may occur in 28% of the cases. If it ruptures into subarachnoid space of the brain, it can cause severe anaphylactic reactions. Microsurgical removal is another option, particularly for cysts in deep or eloquent brain areas, where the initial stage of the procedure is performed under a micro- scope, although the delivery process is conducted without one [20]. The PAIR (Puncture, Aspiration, Injection, Re-aspiration) is a minimally invasive technique which is very rarely used for cerebral hydatid cysts due to the higher risk of complications [21]. Medical treatment with albendazole and praziquantel can be considered, particularly in recurrent cases or when rupture occurs during surgery.[9,22] In the case of successful removal of the cyst, the patient prognosis is quite good. Hydatid cysts should be considered when a large brain cyst is encountered. Slow growth, the patient's background, and a history of recent travel might provide helpful clues for diagnosis. Preoperative diagnosis and meticulous surgical dissection during surgery might ensure complete patient recovery.

Adult age, solitary presentation, and supratentorial localization—although relatively infrequent—are well-documented features of cerebral hydatid disease and therefore cannot be considered exceptional. Several published series have reported adult patients with solitary supratentorial cysts, particularly in the parietal and temporoparietal regions, reflecting hematogenous dissemination along the middle cerebral artery territory. In contrast, the truly atypical feature in the present case is the presence of peripheral ring enhancement with surrounding perilesional edema, imaging findings that are classically absent in uncomplicated intracranial hydatid cysts. Such features are usually associated with cyst rupture, secondary infection, or an inflammatory host response. However, only a limited number of previously reported cases describe similar radiological characteristics, and a more explicit comparison with these reports would strengthen the interpretation of this finding as an unusual presentation rather than an incidental variation.

The atypical imaging profile explains the initial diagnostic ambiguity and underscores the importance of maintaining a high index of suspicion for hydatid disease in endemic regions, even when classical imaging features are absent. Given the limited sensitivity of serological tests in isolated cerebral involvement, definitive diagnosis continues to rely on intraoperative and histopathological confirmation, as was the case in our patient.

Limitation

Although the one-year follow-up in the present case is acceptable for a case report and demonstrated no evidence of recurrence, the duration remains relatively short for fully assessing long-term recurrence risk. This limitation will be acknowledged, as late recurrence has been reported in cerebral hydatid disease, particularly in cases complicated by intraoperative cyst rupture.

CONCLUSION

Echinococcosis is a common disease endemic in the central belt of India, usually involving the liver and lungs. Intra- cerebral hydatid cysts being rare, it can be dangerous if not diagnosed and treated accordingly. Intra-cerebral hydatid cysts have slow growth rate and are symptomatic in later stages causing high morbidity and mortality. Imaging modalities like computed tomography and magnetic resonance imaging supports in establishing diagnosis of hydatid disease, but if unusual anatomic sites with atypical imaging findings present themselves; Neurosurgeons have to bear in mind hydatid cysts when evaluating cystic lesions in the brain. In atypical cases, surgical techniques may vary, and careful dissection of the cyst capsule from the brain parenchyma can be successful with minimal risk of intraoperative rupture.

ACKNOWLEDGMENTS

With special thanks to the neurosurgery,pathology and radiology department of SVP Hospital

CONFLICT OF INTEREST

None declared

Image Ladder

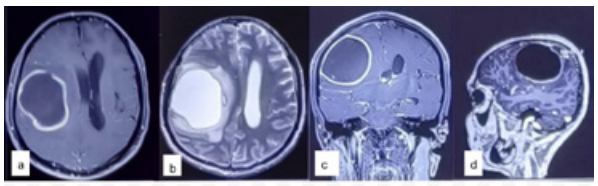

Figure 1:- Contrast enhanced MRI Brain a) T1 contrast axial image showing cystic lesion with ring enhancement in right temporoparietal lobe, b) T2 weighted axial image, c) T1 contrast coronal image, d) T1 contrast sagittal image

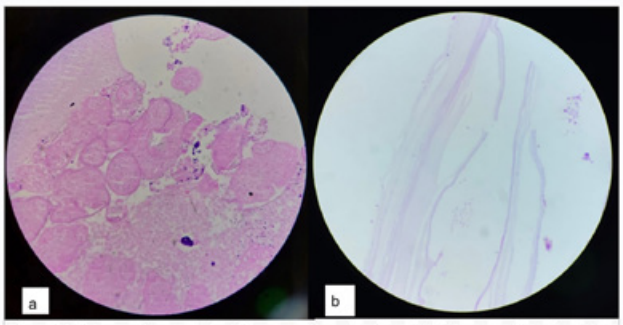

Figure 2: Microscopic examination (hematoxylin and eosin stain) of the cyst a;Reactive glial tissue covered by thin layer of inflammatory cells along with fragments of chitinous layer and protoscolices, b;a laminated acellular wall with a nucleated germinal layer.

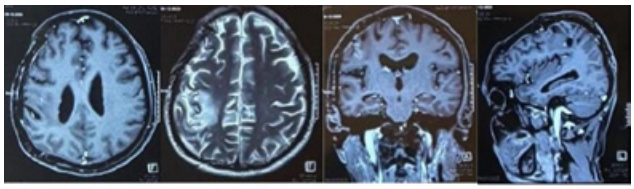

Figure 3:- Post OP Contrast enhanced MRI Brain after 03 month A) T1 contrast axial plate showing complete removal of cyst with no residual cyst, B) T2 weighted axial image, C) T1 contrast coronal image. D) T1 contrast sagittal image

REFERENCES

1.Akdemir, G., Daglioglu, E., Secer, M., Ergungo,r M.F. Hydatid cysts of the internal acoustic canal and jugular foramen. J Clin Neurosci. 2007,14,4,394-396. [PubMed ID: 17270448]. https://doi.org/10.1016 j.jocn.2006.04.007.

2. Roquer, J., Escudero, D., Guelar, A., Herraiz, J., Canas, A., Maso, E. et al. Calcified cerebral hydatid cyst in a patient with abdominal hydatidosis. Med Clin .Barc, 198,85,11,458-460. [PubMed ID: 4068813].

3. Boop, F.A., Jacobs, R.F., Young, R.L. Brain abscess and encephalitis in children. In: Albright AL, Pollack IF, Adelson PD, editors. Principles and Practice of Pediatric Neurosurgery. New York: Thieme, 1999, p. 1203-1226.

4. Abdulla, K., Tapoo, A.K., Agha, H.S. Ruptured cerebral hydatid cyst: a case report. J Trop Med Hyg. 1988,91,6,302-305. [PubMed ID: 3204645].

5. Ona,l C., Erguvan-Ona,l R., Yakinci, C., Karayol, A.,, Atambay M., Daldal, N. Can the requirement of a diversion procedure be predicted after an uncomplicated intracranial hydatid cyst surgery? Pediatr Neurosurg. 2006,42,6,383-386. [PubMed ID: 17047420]. https://doi.org 10.1159/000095570.

6. Kammerer, W.S. Echinococcosis affecting the central nervous system. Semin Neurol. 1993,13,2,144-147. PubMed ID: 8356347,. https://doi.org/10.1055/s-2008-1041118.

7. Abbassiou, K., Amirjamshidi, A. Diagnosis and Management of Hydatid Cyst of the Central Nervous System: Part 1: General Considerations andHydatid Disease of the Brain. Neurosurg Q. 2001,11,1,1-9. https://doi.org/10.1097/00013414-200103000-00001.

8. Lunardi, P., Missori, P., Di Lorenzo, N., Fortuna, A. Cerebral hydatidosis in childhood: a retrospective survey with emphasis on long-term follow-up. Neurosurgery. 1991,29,4,515-17. [PubMed ID: 1944831].

9. Altas, M., Serarslan, Y., Davran, R., Evirgen, O., Aras, M.,, Yilmaz N. The Dowling-Orlando technique in a giant primary cerebral hydatid cyst: A case report. Neurol Neurochir Pol 2010,44,304-307.

10. Arana Iniguez, R. Echinococcus. Infection of the nervous system. In: Vinken PJ, Bruyn GW, editors. Hand book of clinical neurology, part III. Amsterdam: Elsevier/North Holland Biomedical Press; 1978. p. 175-208.

11. Evliyaoglu, C., Keskil, S. Possible spontaneous "birth" of a hydatid cyst into the lateral ventricle. Childs Nerv Syst. 2005,21,5,425-428. PubMed ID: 15580516. https://doi.org/10.1007/s00381-004-1042-z.

12. Limaiem, F., Belli,l S., Bellil, K.,, Chelly, I., Mekni, A., Khald,i M. et al. Primary

hydatidosis of the central nervous system: a retrospective study of 39 Tunisian cases. Clin Neurol Neurosurg. 2010,112,1,23-28. PubMed ID: 19781849. https://doi.org/10.1016/j.clineuro.2009.09.001.

13. Kocaman S, Ersahin Y, Mutluer S. Cerebral hydatid cysts in children. J Neurosci Nurs. 1999;31(5):270-7. [PubMed ID: 10633303].

14. Carrea, R., Dowling, E.J., Guevara, J.A. Surgical treatment of hydatid cysts of the central nervous system in the pediatric age (Dowling's technique). Childs Brain. 1975,1,1,4-21. PubMed ID: 1175437.

15. Menkü, A., Kulaksizoglu, O., Tucer, B.,, Kurtsoy A., Akdemir, H: Successful surgical excision of a gigantic cerebral hydatid cyst. Minim Invasive Neurosurg. 2004, 47,61-64

16. Schantz, P.M., Gottstein, B: Echinococcosis (hydatidosis). Immunodiagnosis of Parasitic Diseases, Volume 1. Academic Press, San Diego, CA; 1986, 69-107.

17. Nemati, A., Kamgarpour, A., Rashid, M., Nazari, S.S.: Giant cerebral hydatid cyst in a child: a case report and review of the literature. Br J Gen Pract. 2010, 3,a338.

18. Handa, U., Ba,l A., Mohan, H.Cytomorphology of hydatid disease . Internet J Tropical Med. 2004, 2,6.

19. Arana-Iniguez, R. , San Julian, J. Hydatid cysts of the brain . J Neurosurg. 1955, 12,323-335.

20. . Balak, N., Çavumirza,C., Yildirim,,H., O ¨zdemir, S.,Kinay, D. Microsurgery in the removal of a large cerebral hydatid cyst: Technical case report, Neurosurgery 59 ,4 SUPPL. 2, 2006.

21. N. O ¨rmeci, PAIR vs O ¨rmeci technique for the treatment of hydatid cyst, Turkish J Gastroenterol. 2014, 25 ,4,358–364.

22. Todorov, T., Vutova, K., Petkov, D., Balkanski, G. Albendazole treatment of multiple cerebral hydatid cysts: Case report. Trans R Soc Trop Med Hyg 1988,82,150-152.